

dogs become suddenly lame and very often have strained or sprained their arthritic elbow or have developed secondary infections in these joints.

Radiographs (x-rays) taken at that time often reveal advanced arthritic changes in their elbows.

A joint centesis (where a sample of the joint fluid is removed) is recommended in these older arthritic joints to differentiate between simple arthritis and secondary infection. Whatever the cause for these old, arthritic joints becoming aggravated, these are best treated medically with various forms of pain relievers, joint lubricating drugs and anti-inflammatory medications. In certain patients, physical therapy will be recommended.

Elbow Registry

Recently, the Orthopedic Foundation for Animals (OFA) established a registry for dogs whose elbows show no radiographic signs of Elbow Dysplasia. The OFA provides a similar certification for Hip Dysplasia. By certifying dogs with good elbows for breeding, the OFA hopes that the incidence of Elbow Dysplasia will decrease. Your veterinarian can provide you with information on the elbow and hip certification process.

Summary

Elbow Dysplasia is being diagnosed more frequently because of an increased awareness of the disease process and improved diagnostic techniques. Early diagnosis is essential if surgical treatment is to be of value in relieving discomfort and removing some of the sources of irritation that can lead to arthritis.

As with Hip Dysplasia, early radiographic screening of the elbow joints is recommended. This procedure very often can be done at the time of spaying or neutering (typically 6 months of age). Since the problem is genetic in nature, dogs with Elbow Dysplasia should not be used for breeding.

Veterinary Surgical Centers of the Delta will be happy to answer your questions about the screening and treatment of Elbow Dysplasia.

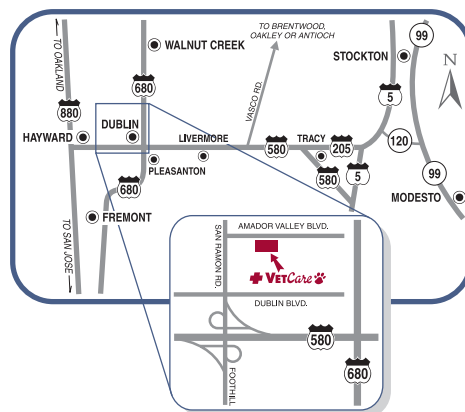
VETERINARY

SURGICAL CENTERS OF THE DELTA

Visit Us at Our Two Locations...



Conveniently located at the
680-580 interchange in Dublin, CA
7660 Amador Valley Boulevard • Dublin, CA 94568
Phone: (925) 556-1234 • Fax: (925) 556-1299
Come visit us and tour our facilities at:
www.emergencyvetcare.com

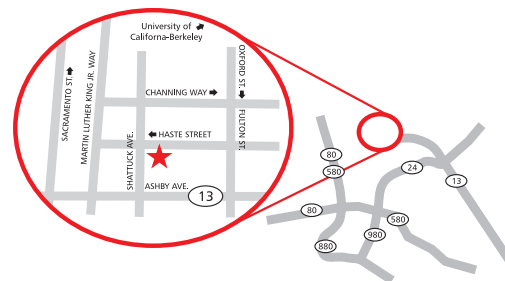


BERKELEY DOG & CAT HOSPITAL



SPECIAL VETERINARY SERVICES

Our historic hospital is located near the
campus entrance of UC Berkeley
2126 Haste Street • Berkeley, CA 94704
Phone: (510) 848-5041 • Fax: (510) 548-4071
www.specialvetservices.com




VETERINARY

SURGICAL CENTERS OF THE DELTA

The Elbow

Treatment of Canine Elbow Dysplasia



Come. Sit. Stay.
Heal...

Canine Elbow Dysplasia

Elbow dysplasia is a genetic disorder that occurs when the bones of the elbow joint fail to develop properly, resulting in misalignment, uneven joint surfaces and stress points. This problem occurs in young dogs, especially large breeds such as Labrador retrievers and Rottweilers, although it can occur in other breeds as well. Since it is hereditary, care should be taken to avoid breeding dogs with elbow dysplasia.

Symptoms of this condition include forelimb lameness and sometimes swelling of the elbow. The extent of symptoms and discomfort depends upon the severity of the disease and your dog's tolerance to pain. In many animals, the condition occurs in both elbows.

The elbow is made up of three bones: the humerus, radius and ulna (fig. 1) During a dog's rapid growth phase, usually between 4-9 months of age, these bones fail to grow in harmony. The result is an uneven joint surface and 'stress' points in the elbow joint.

At the very least, this condition predisposes the elbow to premature wear. In many cases, the stress points become severe enough to cause bone or cartilage fragments to break off. These fragments in the joint feel similar to a stone in the shoe. These fragments also increase discomfort and often hasten the onset of arthritis. The most common fragments occur in the areas of anconeal process (fig. 2), medial coronoid process (fig. 3a) and on the medial humeral condyle (fig. 3b). These conditions are called Ununited Anconeal Process, Fragmented Coronoid Process and Osteochondrosis of the Elbow.

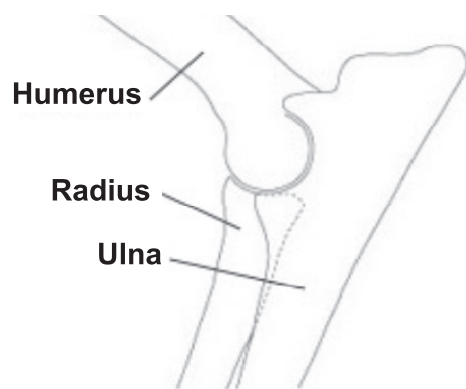


Fig. 1

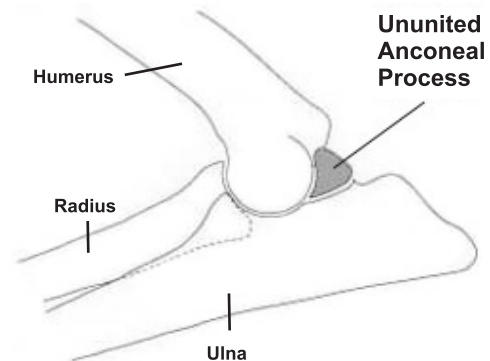
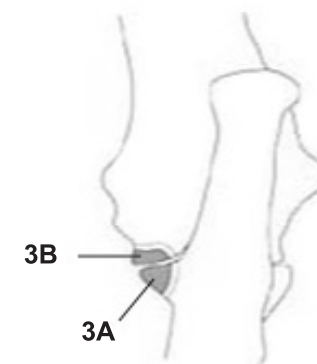


Fig. 2



3A - Fragmented Coronoid Process
3B - Osteochondrosis of the Elbow

Fig. 3

Diagnosis

Since Elbow Dysplasia is not the only cause of forelimb lameness, it is important to have your pet carefully examined to ensure that an accurate diagnosis is made and appropriate treatment instituted.

A physical examination is very useful in localizing the cause of the lameness. By observing your dog move and by palpating the limb(s), the veterinarian is often able to isolate the specific bone or joint responsible for the lameness. Radiographs (x-rays) may show if any bone fragments are present within the joint and whether or not arthritis has developed.

Early in the disease process, bone and cartilage fragments may not be visible on the radiographs. In these cases, additional tests such as CT scan can be of great help. This special imaging detects joint problems at a very early stage. Once the diagnosis is established, treatment can be initiated.

Treatment

The treatment of Elbow Dysplasia depends on the severity of the disease and at what stage it is diagnosed. If the disease is recognized in a young dog and the elbow has minimal arthritic changes, surgical intervention can help. The conditions within the elbow will determine which, if any, surgery is available. The goals of surgery are to remove the sources of joint irritation and, in severe cases, to improve joint mechanics by improving bone alignment. Even after surgery, some dogs may continue to have

lameness and may need to be restricted from heavy exercise, i.e., Frisbee or ball playing.

In the early stages of elbow dysplasia, where there is minimal malalignment, the joint is explored arthroscopically and any fragments are removed through small openings in the joint. This eliminates the 'stone-in-the-shoe' effects of the disease, and has proven adequate to relieve discomfort and swelling. Following surgery, your dog should have restricted activity for approximately four weeks.

When more severe bone deformity occurs, the surgeon cuts the ulna bone to expose the entire joint, remove any fragments and adjust the alignment of the bones. The ulna is then sometimes repaired with stainless steel pins, and wire. The pins and wire remain in place as long as they do not move or otherwise irritate your pet. Aftercare is more involved with this procedure, requiring restricted activity for 6-8 weeks. Complete instructions for home care are provided and your dog's recovery progress is checked at regular intervals following surgery.

With each of these techniques, there is approximately a 70-80% chance of significant improvement. Some dogs may continue to have lameness and need to be restricted from heavy exercise following recovery from surgery.

In some cases of Elbow Dysplasia, dogs may not show symptoms of this disease until their later years, after they have developed significant arthritis. Sometimes these